Combined Pituitary Hormone Deficiency in a Libyan Family

Mutwakil G. Ahmed,* Almahdi W. Alamin,* Hossin I. Mohamed,* Mohamed Y. El-Khalifa,**
Mohamed M. Ahmed,** Farag O. Matoug,*** Mahmoud H. Milad,***

Abstract:
We report a familial form of combined pituitary hormone deficiency (CPHD) in a Libyan family of a rural area of Fezan region, south Libya. The index case was an 18-year-old, male, secondary school student referred to the medical department at 2nd March Teaching Hospital for assessment of severe growth retardation. Born to a first-degree cousin parent, his height was 109 cm and weight was 20 kg. Hormonal assay revealed CPHD. The familial screening examined the six siblings of the index patient and the parents. Four siblings had a clinical presentation of CPHD. The CPHD phenotype in the present family was characterized by severe dwarfism and a lack of spontaneous puberty.
None of the affected patients had blue sclera or limitation of elbow extension described in previous families. All patients had undetectable levels of growth hormone (GH) < 0.2 ng/ml and Luteinizing hormone (LH) < 0.10 mlU/ml. Thyroid hormone levels were below normal in four patients. Corticotroph (ACTH) deficiency was detected in three patients at an early age in contrast to previous reports.
Arrangements are underway for genetic screening of the present family for the detective gene. Such genetic screening would prove useful to the clinical management of the affected children since it permits an earlier diagnosis of the hormone of gradual onset, especially thyroid stimulating hormone (TSH) and corticotroph (ACTH) deficiencies. Moreover, it allows anticipating gonadotroph deficiency at pubertal age.

Introduction:
Combined pituitary hormone deficiency (CPHD) is a disorder characterized by impaired production of growth hormone (GH) and one or more of the other anterior pituitary hormones. Aside from short stature, clinical features include hypothyroidism, impaired sexual maturation and hypocortisolism, either individually or simultaneously.[1]
CPHD may result from acquired lesions in the hypothalamic-pituitary area (tumor, trauma, surgery or irradiation) or from genetically defined conditions or they may be idiopathic. Congenital CPHD is usually sporadic, but nearly 10% of cases are familial.[2,3]
Genetic defects in the development and function of the pituitary gland can result in various forms of CPHD.[4-12]
Here we report a familial form of combined pituitary hormone deficiency "CPHD" in a Libyan family.

Patients and Methods:
Patients:
All of the patients belonged to the same family of a rural area of Fezan zone, south Libya, characterized by a high degree of consanguinity. The index case was initially referred to the medical department of 2nd March Teaching Hospital for investigation of severe growth retardation. A thorough clinical, haematological, biochemical and radiological work up was conducted. Because he was found to have a family history of severe dwarfism affecting several of his siblings, all of them and the parents were then investigated.
After an informed consent stature was measured in centimeters using a meter attached to the wall with the average of three measurements recorded. Weight was measured with a balance-beam scale. The body mass index (BMI) was calculated with weight in kilograms divided by the square of height in meters. Tanner's sexual maturity rating system was used to assess genital changes.
Biochemical analysis:
Growth hormone (GH) was measured by a commercial radio-immuno-assay kit. Basal plasma adrenocorticotrophic hormone (ACTH) and cortisol were measured at 08:00 h.

*) Department of Medicine, Faculty of Medicine, Sebha University, Sebha – Libya.
**) Department of Paediatric, Faculty of Medicine, Sebha University, Sebha – Libya.
***) Department of Radiology, Faculty of Medicine, Sebha University, Sebha – Libya.

Investigation of the gonadotrophin axis was performed by measurement of luteinizing hormone (LH) and follicular stimulating hormone (FSH) levels at base-line together with basal testosterone and estradiol. Basal prolactin, thyroid stimulating hormone (TSH), tri-iodothyronine (T_3) and thyroxine were assayed.

Radiological imaging:
Lateral skull X-ray films were examined for sellar area. Magnetic resonance (MRI) examinations of the pituitary gland were performed using coronal spin echo T_1-weight images.

Results:
Patients' characteristics
We have studied members of a consanguineous family from a geographically isolated rural area of south Libya (Hamera, Murzuk region, Fezan governate).
The index case was on 18-year-old male, secondary school student patient referred for severe growth retardation, to the Department of Medicine at 2nd March Teaching Hospital, Sebha, south Libya. Born to a first-degree cousin parents, his height was 109 cm and weight was 20 kg, (Table 1).
He has the so-called doll-like aspect and marked frontal bossing suggestive of somatotroph deficiency. This was confirmed by endocrine investigations (Table 2) showing complete growth hormone deficiency, with an undetectable GH concentration (Peak < 0.2 ug/L). Basal cortisol, ACTH and TSH were normal, whereas T_4 (23.6 nmol/L) and T_3 (0.51 nmol/L) were low.
The gonadotrophin axis evaluation revealed low levels of FSH (0.46 mlU/ml), LH (< 0.10 mlU/ml), testosterone (<0.02 ng/ml) and progesterone (0.09 ng/ml). Estradiol level (24.9 pg/ml) was normal, (Table 3).

The familial screening examined the six siblings of the index and the parents. Four siblings had a clinical presentation of CPHD (Tables 2,3). A total of five affected subjects were thus identified in this consanguineous family of healthy parents, (Fig. 1).

Table 1: Anthropometric characteristics of patients with familial combined pituitary hormone deficiency.

Patient No.	Sex	Age (years)	Height (cm)	Weight (kg)	Tanner*
1	Male	21	127	29	GIPI
2	Male	18	109	20	GIPI
3	Female	13	117	22	BIPI
4	Male	11	111	17	GIPI
5	Female	3	93	13	BIPI

*) Sexual matority rating (Tanner staging).

Table 2: Endocrine investigation of patients with familial combined pituitary hormone deficiency.

Patient No.	Sex	Age (years)	TSH mIU/L	T4 nmol/L	GH ng/ml	ACTH pg/ml	Cortisol nmol/L
1	Male	21	1.5	41.0	<0.2	<1.0	193.1
2	Male	18	0.88	23.6	<0.2	2.5	320.5
3	Female	13	1.3	62.3	<0.2	<1.0	222.3
4	Male	11	3.1	70.4	<0.2	1.2	307.6
5	Female	3	1.7	44.7	<0.2	<1.0	213.3

Table 3: Sex hormone biochemistry in patients with familial combined pituitary hormone deficiency.

Patient No.	Sex	Age (years)	FSH mIU/L	LH mIU/ml	Testosterone pg/ml	Estradiol pg/ml	Prolactin ng/ml
1	Male	21	0.19	<0.10	<0.02	27.89	9.93
2	Male	18	0.46	<0.10	<0.02	24.91	2.92
3	Female	13	0.68	<0.10	<0.07	37.66	9.46
4	Male	11	0.31	<0.10	<0.02	25.37	19.26
5	Female	3	0.19	<0.10	<0.06	25.94	0.08

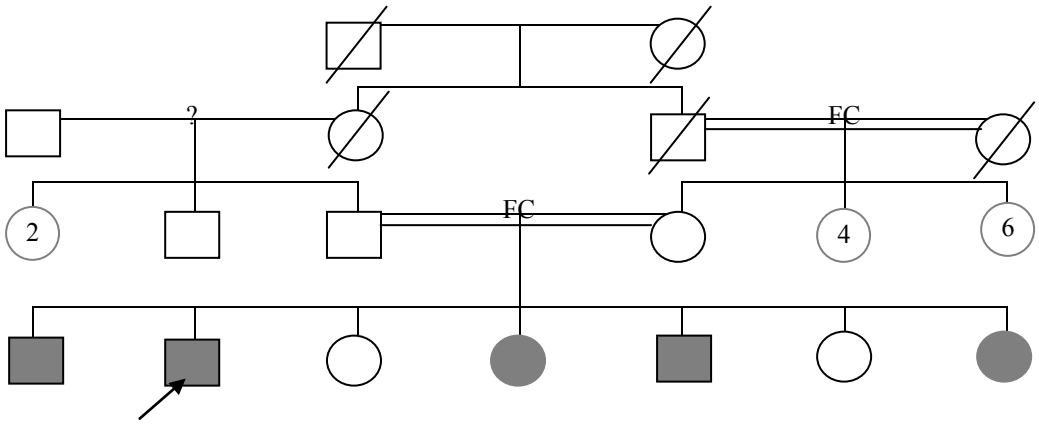

Fig. 1: Pedigree of the index family.

All patients had GH and LH deficiency. All male patients had testosterone deficiency. Three patients had hypothyroidism. Conticotroph deficiency was present in three patients (Table 2, 3). In the two patients beyond the pubertal age, signs of puberty were absent (Table 1). Pituitary MRI studies and skull x-rays were normal.

Discussion:

The last 15 years have witnessed considerable advances in the understanding of anterior pituitary ontogenesis by the identification of several transcription factors including Pit1, PROP1, HESX1, LHX3, LHX4, PITX1, PITX2 and TPIT.[13-20]

These nuclear proteins act in concert with other factors to control the differentiation and the development of one or more anterior pituitary cell lineages. Both in humans and in animal models, alterations affecting the genes encoding these factors may lead to sporadic or familial forms of anterior pituitary hormone deficiency. These may affect either a single hormone cell type[20] or several cell lineages as in combined pituitary hormone deficiency, CPHD.[21-23]

Propl gene alterations currently represent the most frequently recognized form of genetically determined CPHD in man. Prop1 is a paired like homeobox gene mapped to chromosome 5q in humans. At least 15 PROP1 gene allelic variants have currently been found in association with a human CPHD phenotype transmitted as a recessive autosomal trait.

The CPHD in the present was characterized by an extremely short stature with none of the patients aged 18 years or older exceeding 127 cm in height. Our patients had no spontaneous onset of puberty like most of previously reported cases.

Other previous familial studies reported 14 Tunisian patients, eight Dominican patients and 10 Brazilian patients with CPHD.[8,9,11]

A fourth study was related to the "Little people" of Krk Island including six patients from two related families historically reported as having familial panhypopituitarism.[24]

Clinical presentation in previous family studies included blue sclera[11] and limitation of elbow extensibility[8,11] which were not observed in our patients.

Although corticotroph deficiency had been initially described as a late complication affecting patients over 40 years,[11] three of our deficient patients were aged 3-21 years in consistence with the Tunisian kindred.[9]

Thyroid hormone levels were below normal in all of the affected patients, except in one 11-year-old boy in agreement with two previous studies.[9,25]

Anterior pituitary enlargement on MRI, among patients CPHD, reported in a previous study[9] was not seen in our patients. However, in some instances longitudinal follow up revealed this aspect might precede anterior pituitary hypoplasia.[26]

In conclusion, the CPHD phenotype in the present family was characterized by severe dwarfism and a lack of spontaneous puberty. None of the affected patients had blue sclera or limitation of elbow extensibility described in previous families. All the affected five patients had undetectable levels of GH and LH. Thyroid hormone levels were below normal in four patients. Corticotroph deficiency was seen in three patients in an early stage in this population in contrast to previous studies.

Arrangement are underway for genetic screening of the present family for the detective gene. Such genetic screening is useful to the clinical management of the affected children because it permits an earlier diagnosis of the hormone deficits of gradual onset, especially thyrotroph and corticotroph deficiencies. Moreover, it allows anticipating gonaodotroph deficiency at pubertal age.

References:

1. Ulera T.C., Dias M.R., Cerutti J.M et al. Familial combined pituitary hormone deficiency due to a novel mutation of R99G in the hot spot region of prophet of pit 1 presenting as constitutional growth delay. J. Clin endocrinol Metab. 2003; 88(1): 38-44.
2. Procter A.M., Philips I.J. and Cooper D.N. The molecular genetics of growth hormone deficiency. Hum. Genet. 1998; 103: 255-257.
3. Cogan J.D., Wu W., Phillips III J. A. et al. The Prop1 2-base pair deletion is a common cause of combined pituitary hormone deficiency. J. Clin. Endocrinol Metab. 1998; 83: 3346-3349.
4. Parks J.S, Brown M.R., Hurley D.L., et al. Heritable disorders of pituitary development. J. Clin. Endocricol. Metab. 1999; 84: 4362-4370.
5. Olson L.E. and Rosenfield M.G. Genetic and genomic approaches in elucidating mechanisms of pituitary development. Endocrinology. 2002; 143: 2007-2011.
6. Kopp P. Genetic defects in the etiology of congenital hypothyroidism. Endocrinology. 2002; 143: 2019-2024.
7. Pfaffle R.W., Blankenstein O. Wuller S. et al. Combined pituitary hormone deficiency: role of pit1 and prop1. Acta paediat. Suppl. 1999; 88: 33-41.
8. Pernasetti F., Toleds S.P., and Vasilyev V.V. Impaired adreno-corticotropin-adrenal axis in combined pituitary hormone deficiency caused by a two-base pair deletion (301-302 del-AG) in the prophet of pit 1 gene. J. Clin. Endocrinol. Metab. 2000; 85(1): 390-397.
9. Reynaud R., Chadli-chaieh M., Vallette-Kosic S. et al. A familial form of congenital hypopituitarism due to prop1 mutation in a large kindred: phenotypic and in vitro functional studies. J. Clin. Endocrinol. Metab. 2004; 89(1): 5779-5786.
10. Osario M.G., Kopp P., Marui S. et al. Combined pituitary hormone deficiency caused by a novel mutation of a highly conserved residue (F88S) in the homedomain of prop 1. J. Clin. Endocrinol. Metab. 2000; 88(8): 3779-3785.
11. Rosenbloom A.L., Almonte A.S., Brown M.R. et al. Clinical and biochemical phenotype of familial anterior hypopituitarism from mutation of the prop1 gene. J. Clin. Endocrinol. Metab. 1999; 84: 50-57.
12. Wu W., Cogan J.D., Pfaffle R.W. et al. Mutations in prop1 cause familial combined pituitary hormone deficiency. Nat. Genet. 1998; 18: 147-149.
13. Li S., Crensbaw EB, Rawson EJ, et al. Dwarf locus mutants lacking three pituitary cell types result from mutation in the POU domain gene Pit-1. Nature. 1999; 347: 528-533.
14. Somson MW, Wu W, Dasen JS, et al. Pituitary lineage determination by the prophet of pit 1 homedomain factor defective in Ames dwarfism. Nature. 1996; 384: 327-333.
15. Dattani MT, Martinez BP, Thomas PQ, et al. Mutations in the homebox gene HESX1 associated with septo-optio dysplasia in human and mouse. Nat Genet. 1998; 19: 125-133.
16. Sheng HZ, Zhadanou AB, Mosinger JB, et al. Specification of pituitary cell lineage by the LIM homebox gene LHX3. Science. 1996; 272: 1004-1007.
17. Sheng HZ, Moriyama K, Yamashita T, et al. Multistep control of pituitary organogenesis. Science. 1997; 278: 1809-1812.
18. Lanctot C, Lamolet B, and Drouin J. The bicoid-related homeprotein PTX1 defines the most anterior domain of the embryo and differentiates posterior from anterior lateral mesoderm. Development. 1997; 124: 2807-2817.
19. Muccielli ML, Martinez S., Pattyn A., et al. OTLX2, an OXT-related homebox gene expressed in the pituitary gland and in a restricted pattern in the forebrain. Mol Cell Neurosci. 1996; 8: 258-271.
20. Lamolet B. Pulichino A, Lamonerie T., et al. A pituitary cell-restricted T box factor, T pit actwales POMG transcription in cooperation with pit X homeoprotein. Cell. 2001; 104: 849-859.

21. Cohen LE, Radovick S. Molecular basis of combined pituitary hormone deficiency. Endocr Rev. 2002; 23: 431-442
22. Radovick S, Nations M, Du Y, et al. A mutation in the POU-homeodomain of Pit-1 responsible for combined pituitary hormone deficiency. Science. 1992; 257: 1115-1118.
23. Nitchine I, Sorbrier ML, Krude H, et al. Mutations in LHX3 result in a new syndrome revealed by combined pituitary hormone deficiency. Nat Genet. 2000; 25: 182-186.
24. Krzinik C, Kolacio Z, Battelino T, et al. The "little people" of the island of Krk – revisited etiology of hypopituitarism revealed. J. Endocrine Genet. 1999; 1: 9-19.
24. Deladoey J, Fluck C, Buyukgebiz A, et al. "Hot spot" in the Prop1 gene responsible for combined pituitary hormone deficiency. J Clin Endocrinol Metab. 1999; 84: 1645-1650.
25. Teinturier C, Vallette S, Adamsbaum C, et al. Pseudotumor of the pituitary due to prop-1 gene deletion. J Pediatr Endocrinol Metab. 2002; 15: 95-101.