Malignant Chest Wall Tumors
Part (1)

Emhmed Saaid,* Mutwakil G. Ahmed,** Mahmoud H. Milad,* Carlo Cireco,***

Abstract:
Malignant chest wall tumors typically manifest as large, poorly marginated infiltrative masses and are more likely than benign tumors to be symptomatic. Although most malignant tumors have a nonspecific imaging appearance, findings such as chondroid or osteoid matrix, combined fat and soft tissue components or diffuse osteolytic change in association with a soft-tissue rib mass can be helpful in suggesting diagnosis of chondrosarcoma or osteosarcoma, liposarcoma, or multiple myeloma respectively.
Changes in benign lesions such as the development of a soft tissue mass in association with pre-existing osteochondroma or the loss of a target like appearance in neurofibroma may be early indications of malignant transformation. In some patients, the combined clinical and imaging findings may suggest the diagnosis. For example, findings of chronic lymphedoema may lead to a diagnosis of angiosarcoma, or findings of a large mass with relatively minor rib involvement in a child may indicate a diagnosis of Ewing sarcoma. Even when the findings are nonspecific, imaging is important for tumor staging, therapeutic planning, and follow up of patients with malignant chest wall tumors.
However, many chest wall tumors have nonspecific imaging features, and histological analysis of tissue specimens is frequently required for diagnosis. Even after the decision has been made to perform a biopsy, imaging continues to play an important role in tumor management and is frequently used to facilitate biopsy, assess post procedural complications, and perform follow-up evaluation of tumors that are not excised.

Introduction:
Malignant chest wall tumors are classified into eight main diagnostic categories: muscular, vascular, fibrous, fibro histiocytic, peripheral nerve, osseous and cartilaginous, adipose, hematologic, and cutaneous. However, there are malignant tumors that arise in the chest wall and that do not fit well in any of these categories.[1]
Malignant chest wall tumors typically manifest as painful, rapidly growing large palpable masses.
Chest wall radiography, the technique most often used for initial evaluation, can be helpful for detecting cortical destruction. However, computed tomography (CT) is more sensitive than chest radiography for detecting calcified tumor matrix and cortical destruction.[2]
Magnetic resonance imaging (MRI) often allows more accurate delineation and localization of the tumor invasion and for tissue characterization. Although the imaging features of many malignant chest wall tumors are nonspecific, knowledge of the typical radiologic manifestations of these tumors often enables their differentiation from benign chest wall tumors and occasionally allows a specific diagnosis to be suggested.[3]
Chest radiography is often performed at initial evaluation of a clinically suspected malignant chest wall tumor. Although this technique is useful for detecting cortical destruction, a finding indicative of extra-compartmental extension, it does not allow comprehensive assessment of the tumor.[2]
Computed tomography (CT) is more sensitive than chest radiography for detecting calcified tumor matrix and cortical destruction. Furthermore, magnetic resonance (MR) imaging, which has a multiplanar capability and often superior spatial resolution, can provide additional information regarding the extent of the tumor, as well as tissue characterization (Table 1, 2).[3,4]

*) Department of Radiology, Sebha University, Sebha, Libya.
**) Department of Medicine, Sebha University, Sebha, Libya.
***) Department of Radiology, Facalta' Di Medicina E Chirurgia, Italy.

Table 1
Radiologic Differentiation of Malignant Chest Wall Tumors

Imaging Finding	Tumor Type
Fat component	Liposarcoma
Calcification	
Skeletal	
Rings and arcs	Chondrosarcoma
Flocculent or stippled	Chondrosarcoma
Centrally dense	Osteosarcoma
Extraskeletal	
Heterogeneous	Ganglioneuroblastoma or neuroblastoma
Speckled	Proximal-type epithelioid sarcoma
Diffuse osteolytic change	Myeloma
Ill-defined mass	
Eccentric growth, in children and young adults	Ewing sarcoma
Fluid-fluid levels and calcification, in adolescents and adults	Synovial sarcoma
Chronic lymphedema	Angiosarcoma
Infiltrative growth	Malignant lymphoma
Nonspecific findings	Leiomyosarcoma, rhabdomyosarcoma, malignant fibrous histiocytoma, aggressive fibromatosis, malignant peripheral nerve sheath tumor, or dermatofibrosarcoma protuberans

Table 2
Imaging Findings with Clinical and Pathologic Correlation in Malignant Chest Wall Tumors

Tumor Tissue and Type	Patient Age	Frequency of Occurrence	Clinical and Laboratory Findings	Imaging Findings		
				CT	MR Imaging	General
Muscular						
Leiomyosarcoma	Adulthood	Uncommon	Pain; association with acquired immune deficiency syndrome (AIDS), Epstein-Barr virus, organ transplantation	No calcification; displacement or distortion of vessels	T1-weighted images: low signal intensity; T2-weighted images: high signal intensity; ringlike enhancement	Spindle shape
Rhabdomyosarcoma	Adulthood	Rare	Pain; variable histologic findings (embryonal, alveolar, and pleomorphic subtypes)	No calcification	Heterogeneous signal intensity on both T1- and T2-weighted images; low-signal-intensity foci indicate necrosis in alveolar and pleomorphic subtypes; ringlike enhancement	Ill-defined contours; rapid growth; bone invasion (in >20% of patients)
Vascular						
Angiosarcoma	Adulthood	Rare	Association with chronic lymphedema, irradiation, chemical exposure	No calcification	Heterogeneous signal intensity on both T1- and T2-weighted images; sharp enhancement	Ill-defined contours; location in breast
Fibrous and fibrohistiocytic						
Malignant fibrous histiocytoma (MFH)	Adulthood	Uncommon	Variable histologic findings (storiform-pleomorphic and myxoid subtypes)	No calcification	T1-weighted images: signal intensity of muscle; T2-weighted images: signal intensity of muscle or higher	Ill-defined contours; heterogeneous enhancement
Aggressive fibromatosis	Adolescence to early adulthood	Common	Rare association with Gardner syndrome; more often linked with trauma, endocrine disorders, genetic factors	No calcification	T1-weighted images: signal intensity of muscle or lower; T2-weighted images: heterogeneous signal intensity	Ill-defined contours; heterogeneous enhancement; multiple lesions
Peripheral nerve						
Neuroblastoma and ganglioneuroblastoma	Early adulthood	Rare	Variable component of mature glial and ganglion cells	Spotty calcification	T1-weighted images: low signal intensity; T2-weighted images: high signal intensity	Ill-defined contours; location in sympathetic ganglia; pleural dissemination
Malignant peripheral nerve sheath tumor	Adulthood	Uncommon	Frequent association with type 1 neurofibromatosis	No calcification	T1-weighted images: signal intensity of muscle or higher; T2-weighted images: high signal intensity	Ill-defined contours; heterogeneous enhancement; necrosis

(continued)

Table 2
Imaging Findings with Clinical and Pathologic Correlation in Malignant Chest Wall Tumors

Tumor Tissue and Type	Patient Age	Frequency of Occurrence	Clinical and Laboratory Findings	Imaging Findings		
				CT	MR Imaging	General
Osseous and cartilaginous						
Chondrosarcoma	Early or middle adulthood	Common	Wide range of histologic findings	Calcification (rings and arcs, stippled, or dense)	T1-weighted images: variable signal intensity; T2-weighted images: overall high signal intensity; areas of low signal intensity indicate dense mineralization	Variable contours; location in rib; heterogeneous enhancement
Osteosarcoma	Early to middle adulthood	Rare	Pain; frequent local recurrence and metastasis to lungs and lymph nodes	Centrally dense calcification	T1-weighted images: variable signal intensity; T2-weighted images: high signal intensity	Ill-defined contours; typical location at costochondral junction, infrequent extraosseous location; heterogeneous enhancement; degeneration; nodal metastasis
Adipose						
Liposarcoma	Early to middle adulthood	Common	Wide range of histologic findings, includes variable fat and soft-tissue components	Variable	Variable signal intensity	Variable contours; variable enhancement
Myxoid and round cell		Most common subtypes	Primitive mesenchymal cells; rarely metastasizes	Areas of calcification and ossification	T1-weighted images: moderate to high signal intensity; T2-weighted images: high signal intensity	Heterogeneous enhancement
Well-differentiated			Mature fat cells, occasional atypical lipoblasts and giant cells; rarely metastasizes	Capsule with septa	T1-weighted images: low signal intensity; T2-weighted images: high signal intensity	Attenuation or signal intensity of fat
Dedifferentiated			Spindle cell sarcoma combined with well-differentiated liposarcoma	Soft-tissue and fat components	T1-weighted images: areas of high signal intensity interspersed with low signal intensity; T2-weighted images: areas of low signal intensity interspersed with areas of high signal intensity	Heterogeneous enhancement
Hematologic						
Malignant lymphoma	Adulthood	Uncommon	Association with AIDS, metallic implant, immunosuppression	No calcification	T1-weighted images: low signal intensity; T2-weighted images: high signal intensity	Ill-defined contours; infiltrative growth pattern; variable enhancement

(continued)

Table 2
Imaging Findings with Clinical and Pathologic Correlation in Malignant Chest Wall Tumors

Tumor Tissue and Type	Patient Age	Frequency of Occurrence	Clinical and Laboratory Findings	Imaging Findings		
				CT	MR Imaging	General
Solitary myeloma						
Osseous	Adulthood	Common	May progress to multiple myeloma	Calcification; rare sclerosis (caused by fracture, irradiation, or chemotherapy)	T1-weighted images: low signal intensity; T2-weighted images: high signal intensity	Multicystic expansile mass or osteolytic focus without expansion; location in vertebral column, ribs, or clavicles
Extraosseous	Adulthood	Common	Progresses less frequently to multiple myeloma	No calcification	T1-weighted images: low signal intensity; T2-weighted images: high signal intensity	Nonspecific soft-tissue mass
Multiple myeloma	Adulthood	Common	Multiple areas of osteolysis and plasma cell proliferation	Variable calcification	T1-weighted images: low signal intensity; T2-weighted images: high signal intensity	Multiple osteolytic foci with discrete margins
Cutaneous						
Dermatofibrosarcoma protuberans	Adolescence	Uncommon	Palpable mass; frequent recurrence within 3 years of initial treatment	Well-defined subcutaneous nodule with attenuation of muscle or slightly higher; moderate enhancement	T1-weighted images: low signal intensity; T2-weighted images: high signal intensity	Variable contours; may be locally invasive; may include heterogeneous foci due to hemorrhage, myxoid change, or necrosis
Other tumors						
Ewing sarcoma	Childhood to early adulthood	Rare	11;22 chromosomal translocation	Rare calcification	T1-weighted images: signal intensity of muscle or higher; T2-weighted images: high signal intensity	Ill-defined contours; eccentric growth; heterogeneous enhancement
Synovial sarcoma	Adolescence to early adulthood	Rare	X;18 chromosomal translocation	Calcification (in 20%–30% of patients)	T1-weighted images: signal intensity of muscle; T2-weighted images: triple-signal-intensity pattern in large tumors (33% of patients); fluid-fluid levels (15%–25% of patients)	Ill-defined contours; location near joint; septation in large tumors
Proximal-type epithelioid sarcoma	Adolescence to early adulthood	Rare	Lesion may be subcutaneous or deep seated	Ossification or speckled calcification (in 20%–30% of patients)	T1-weighted images: signal intensity of muscle; T2-weighted images: high signal intensity	Multinodular soft-tissue lesion; heterogeneous enhancement; nodal metastasis; attachment to tendon or fascia

Note.—ND = no data available. *Typical patient age at diagnosis.

Leiomyosarcoma

Cutaneous and subcutaneous leiomyosarcomas account for less than 5% of superficial soft-tissue sarcomas. These tumors are frequently painful and typically occur in adulthood, most commonly in men aged 50-70 years. An association of Epstein-Barr virus with leiomyosarcoma has been noted in case reports of children and young adults with acquired immuno-deficiency syndrome (AIDS) and patients who have undergone immuno-suppressive therapy after organ transplantation.[4,5] However, whether Epstein-Barr viral infection plays a role in the pathogenesis of leiomyosarcoma in immunodeficient patients is still unknown. Most primary leiomyosarcoma are solitary lesions; lesion multiplicity suggests metastasis from another site.[6]

CT scans in leiomyosarcoma show a large mass that frequently includes areas of necrotic or cystic change. In addition, displacement or distortion of vessels is often seen.

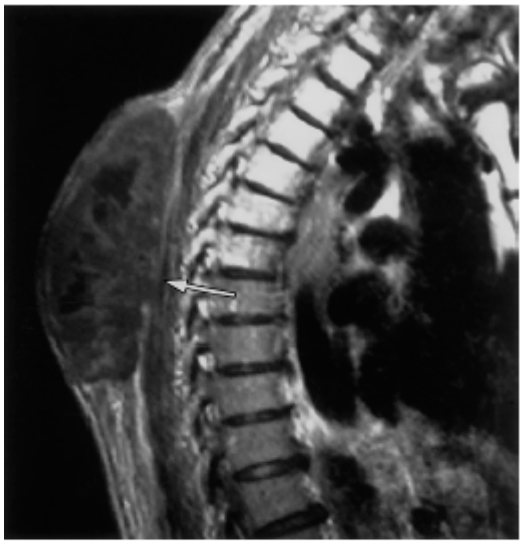

Figure 1. Leiomyosarcoma in a 49-year-old woman. Sagittal T1-weighted (repetition time msec/echo time msec = 600/12) MR image of the spine, obtained after administration of gadolinium-based contrast material, shows a soft-tissue mass with heterogeneous enhancement. Note the enhanced rim or periphery and the central area of low signal intensity. Invasion of the surrounding muscle (arrow) was confirmed at microscopic evaluation of a tissue specimen.

Typical MR imaging features of the mass include a spindle shape and long T1 and T2 relaxation times with resultant relatively low signal intensity on T1-weighted images and high signal intensity on T2-weighted images. A finding of overall low signal intensity or of components with low signal intensity on MR images, however, is not specific to leiomyosarcoma. After intravenous administration of contrast material, tumors typically exhibit an enhanced rim or periphery and a central area of low signal intensity or low attenuation (Fig.1).

Rhabdomyosarcoma

Rhabdomyosarcomas are high-grade sarcomas characterized by skeletal muscle differentiation. They are usually found in patients younger than 45 years of age, in the abdomen, head, or neck. Chest wall involvement is relatively uncommon.

Rhabdomyosarcomas in the chest wall typically manifest as rapidly growing masses (Fig. 2), and may cause pain and other symptoms due to nerve compression. Bone invasion by a primary tumor occurs in more than 20% of patients. There are several histologic subtypes of rhabdomyosarcoma: embryonal, alveolar, and pleomorphic.[7] The alveolar subtype occurs more frequently than the embryonal subtype in the chest wall and extremities, and it has the worst prognosis of all rhabdomyosarcoma subtypes.

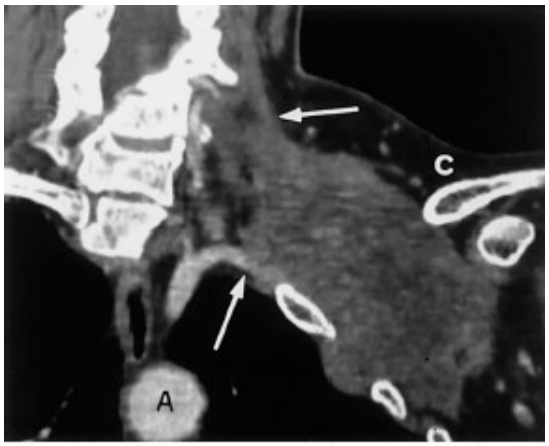

Figure 2. Rhabdomyosarcoma in a 51-year-old woman. Coronal reformatted image of the apex of the left hemithorax from a contrast-enhanced CT study shows a mass that has invaded muscle, fascia, adipose tissue, nerves, and vascular structures (arrows). *A* = aorta, *C* = clavicle.

MR images of pleomorphic and alveolar rhabdomyosarcomas show areas of necrosis with low signal intensity that do not enhance after contrast material administration and that alternate with ring-like areas of high signal intensity and marked enhancement.[8] Alveolar

rhabdomyosarcomas typically include multiple areas of necrosis. Embryonal rhabdomyosarcomas, which typically occur in children, sometimes extend to the anterior and lower chest wall and involve the mediastinum. In all rhabdomyosarcoma subtypes, as in other soft-tissue tumors, CT and MR imaging allow optimal evaluation of tumor extent and medullary involvement.

Angiosarcoma

Angiosarcomas are malignant endothelial neoplasms characterized by vasoformative architecture. Angiosarcomas frequently manifest as large, painful, and rapidly growing masses and are often mistaken for chronic hematomas. They are occasionally associated with hemorrhage, anaemia or coagulopathy.[9]

Chronic lymph edoma is the most widely recognized factor predisposing individuals to angiosarcoma,[10] but this tumor type is also associated with radiation therapy and chemical exposure.

In contrast to malignant cutaneous lesions, which are more often found in the head and neck, angiosarcomas typically originate in the deep soft tissues of the lower extremities.[11]

In the chest wall, angiosarcomas occur primarily in the breast, most often in association with lymph edema or radiation therapy of breast carcinoma. MR images of angiosarcoma show a heterogeneous mass that sharply enhances after intravenous administration of gadolinium-based contrast material (Fig. 3).

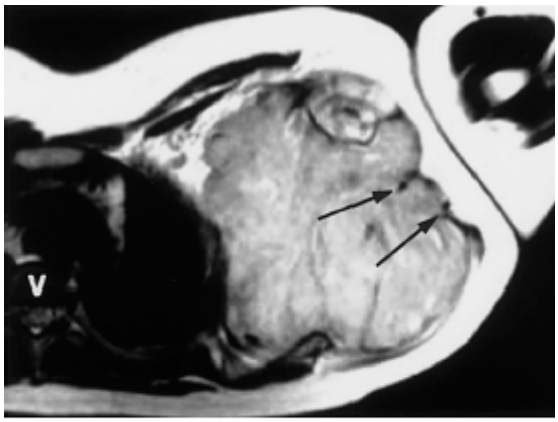

Figure 3. Angiosarcoma in a 67-year-old man. Axi gadolinium-enhanced T1-weighted (600/12) MR image of the apex of the left hemithorax shows an invasi mass with heterogeneous enhancement in the left lateral chest wall. Vascular flow-voids are seen near the surface of the tumor (arrows). *V* = vertebra.

Feeding vessels are often seen in the periphery of the tumor. Fibrous thickening, soft-tissue nodules, increased attenuation in fatty tissue, and fluid collection around muscle characterize angiosarcoma and other tumor types associated with lymph edema.

Malignant Fibrous Histiocytoma

Malignant fibrous histiocytoma (MFH), a soft-tissue sarcoma most often found in older adults, rarely occurs in the chest wall. The tumor typically originates in deep fascia or skeletal muscle and only rarely originates in bone, although involvement of adjacent bone is common.[12] MFH initially was described as having a histiocytic origin, but histogenesis of this tumor type is now uncertain.[13]



a.

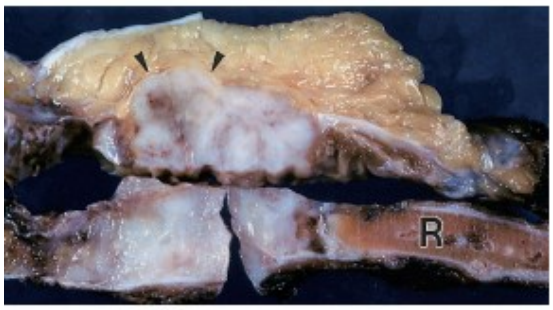

b.

Figure 4. Storiform-pleomorphic malignant fibrous histiocytoma in a 68-year-old woman. (a) Nonenhanced CT scan at the level of the ascending aorta (*A*) shows a destructive mass with origins in the sternum and extension into the surrounding soft tissue (arrowheads). (b) Photograph of the dissected tumor reveals invasion of the subcutaneous tissue (arrowheads). *R* = rib.

Storiform-pleomorphic MFH is the most common form, accounting for more than two-thirds of all cases. MFH manifests on CT scans as a nonspecific heterogeneously enhancing mass in muscle and fascia planes (Fig. 4).

Myxoid MFH is the second most common type, with a characteristic CT appearance of low attenuation in the myxoid matrix at the center of the lesion and nodular peripheral enhancement of the more cellular tumor components.
On T1- and T2-weighted MR images, MFH may appear either homogeneous or heterogeneous. On T1-weighted images, most tumors have signal intensity equal to that of muscle, and on T2-weighted images, they have signal intensity equal to or greater than that of fat.[12] Tumors often show heterogeneous enhancement on MR images obtained with gadolinium-based contrast material.

Aggressive Fibromatosis
Aggressive fibromatosis or desmoid tumor is an infiltrative lesion with an intermediate proliferative tendency, although not as aggressive as the exuberantly proliferative adult fibrosarcoma, it's more aggressive than infantile or congenital fibrosarcoma. The exact pathogenesis is unknown; however trauma, endocrine disorders and genetic factors have been implicated.[14]
Aggressive fibromatosis is a common neoplastic disease and accounts for 54% of low grade sarcomas of chest wall,[11] with shoulder involvement being the most common complication.[15] It often affects adolescents and young adults,[16-19] but may also occur in older patients (Fig. 5).
CT scan shows variable degrees of attenuation and enhancement in accordance with variations in tumor composition. On T1-weighted MR images tumors have signal intensity less than or equal to that of muscle, whereas on T2-weighted images they have mostly intermediate signal intensity.

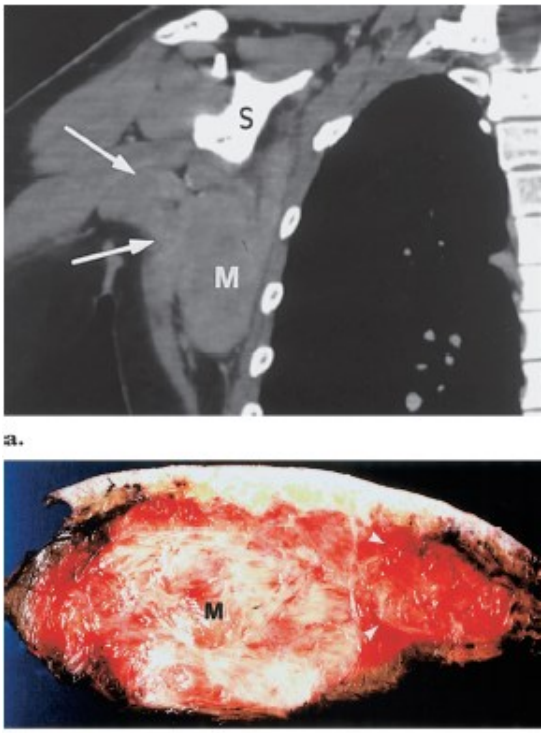

Figure 5. Aggressive fibromatosis in a 38-year-old woman. (a) Coronal reformatted image of the right axilla from a contrast-enhanced multidetector CT study shows a mass (*M*) inferior to the scapula (*S*) with invasion of the surrounding musculature (arrows). (b) Photograph of the resected specimen shows a mass (*M*) of dense trabeculated fibrous tissue with invasion of adjacent structures (arrowheads).

Neuroblastoma and Ganglio-neuroblastoma
Thoracic neuroblastoma and ganglio-neuroblastoma most often occur in the extra-adrenal sympathetic ganglia in the chest wall in children (Fig. 6).[20-22]
Tumors typically manifest as palpable masses and may or may not be accompanied by pain and other symptoms related to the biochemical activity of the tumor.
Neuroblastoma consists primarily of immature neuroblasts, whereas ganglio-neuroblastoma contains a variable component of mature glial cells and ganglion cells.[20-25] CT scans of neuroblastoma show ill-defined tumors, commonly with calcification.

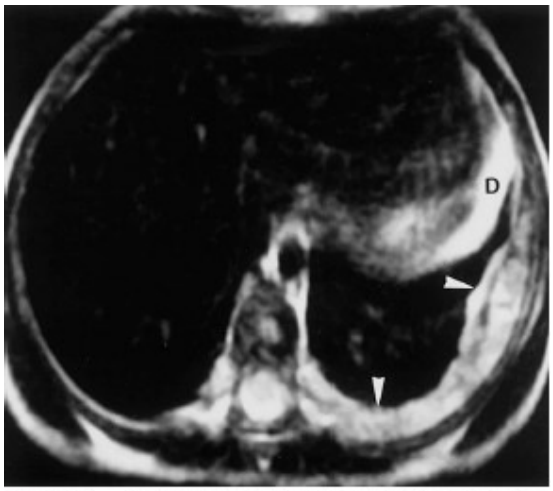

Figure 6. Ganglioneuroblastoma in a 6-year-old girl. Axial T2-weighted (6,000/112) MR image at the level of the diaphragm (*D*) shows a tumor (arrowheads) with heterogeneous high signal intensity extending along the pleural surface.

On MR images, tumors may exhibit heterogeneous and nonspecific signal intensity, although overall low signal intensity is typically observed on T1-weighted images and high signal intensity is seen on T2-weighted images. Intrathecal extension of neuroblastoma is best demonstrated with MR imaging.[20]

Malignant Peripheral Nerve Sheath Tumors

Malignant peripheral nerve sheath tumors, previously known as malignant schwannomas, are neoplasms of nerve sheath origin that both infiltrate locally and metastasize. The tumor usually manifests as a slow-growing mass, pain is more common in patients with type I neurofibromatosis and the development of pain in a neurofibroma portends malignant transformation. In approximately 50% of patients in whom malignant peripheral nerve sheath tumor is diagnosed, an association is found with type I neurofibromatosis.[23]

CT scan of malignant peripheral nerve sheath tumors usually shows a large heterogeneous mass, occasionally accompanied by bone destruction. MR images show a large invasive mass located along the course of a peripheral nerve (Fig. 7). The internal architecture of the tumor may be heterogeneous and irregular in accordance with the extent of necrosis, hemorrhage and cellularity.[24]



Figure 7. Malignant peripheral nerve sheath tumor in a 74-year-old woman. Axial T2-weighted (6,000/112) MR image at the level of the aortic arch (*A*) shows an ill-defined tumor with invasion of bone, fat, muscle and fascia (arrowheads).

Tumors exhibit signal intensity equal to or slightly greater than that of muscle on T1-weighted images. On T2-weighted images signal intensity is markedly increased. Heterogeneous enhancement is observed after intravenous administration of contrast material.[25]

Chondrosarcoma

Chondrosarcomas, the most common malignant primary tumor of the chest wall, usually occurs in the anterior part of the chest wall, arising from the costo-chondral arches or sternum.[26]

Extra-osseous chondrosarcomas are much less common. Nineteen percent of chondrosarcomas occur in the ribs. Most of these are primary lesions, but 10% arise from pre-existing benign tumors.

These tumors occur twice as often in men as in women, and they most frequently are found along the upper five ribs adjacent to costal cartilage.[27]

Bone destruction, irregular contours and intra-tumoral mineralization are characteristic but variable features are detected on chest radiographs.

CT is more sensitive than radiography and MR imaging for delineation of chondroid matrix calcification (Fig. 8a, 9a).

The differentiated chondrosarcomas appear on CT scans as well-defined, densely calcified soft-tissue masses.

T1-weighted MR images show lobulated masses with signal intensity similar to that of muscle, and T2-weighted MR images show masses with signal intensity equal to or greater than that of fat (Fig. 8b, 9b). Enhancement after administration of intravenous contrast material typically is heterogeneous, especially at the periphery.[28-30]

Myxoid chondrosarcomas do not contain chondroid calcifications or bone formation and may have markedly high signal intensity on T2-weighted MR images.

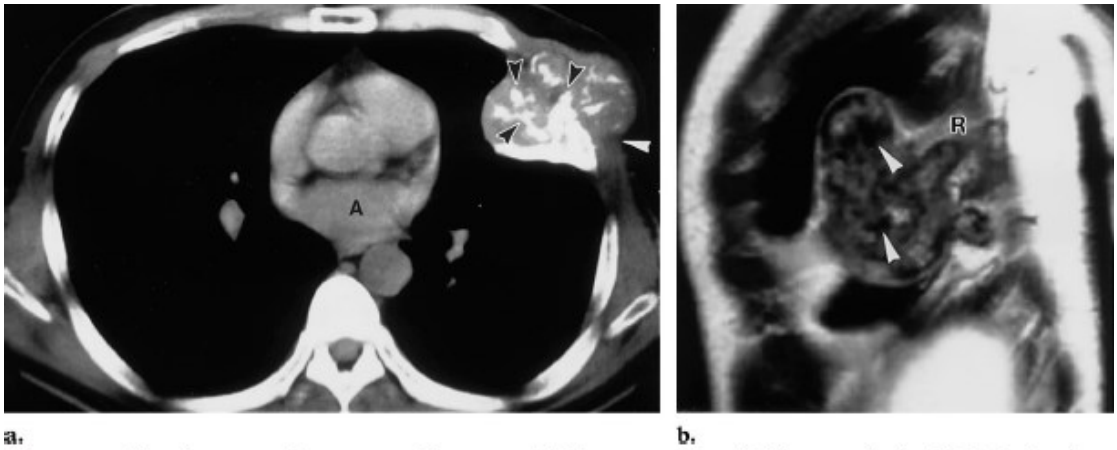

a. b.

Figure 8. Chondrosarcoma in a 19-year-old woman. (a) Contrast-enhanced CT scan at the level of the left atrium (*A*) shows a rib mass with chondroid mineralization (black arrowheads) and invasion of the overlying musculature (white arrowhead). (b) Sagittal T2-weighted (6,000/112) MR image of the lateral chest wall shows a mass arising from the rib (*R*), with a signal intensity higher than that of intercostal muscle. Areas of low signal intensity (arrowheads) indicate dense mineralization in the tumor.

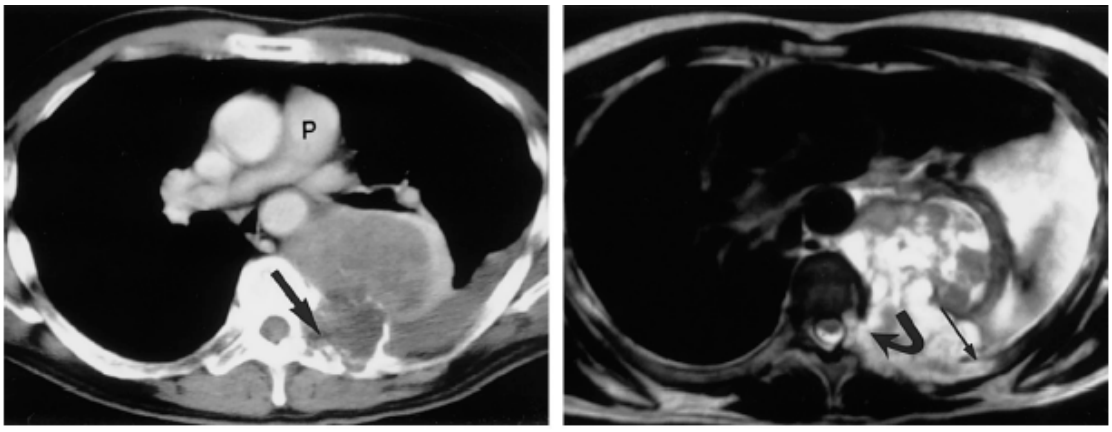

a. b.

Figure 9. Dedifferentiated chondrosarcoma in a 66-year-old man. (a) Contrast-enhanced CT scan at the level of the pulmonary artery (*P*) shows a mass with peripheral calcification (arrow) arising from the costovertebral joint and expanding into the thoracic cavity. Note the small pleural effusion. (b) Axial T2-weighted (4,500/97.7) MR image at the level of the pulmonary artery shows a tumor with heterogeneous high signal intensity extending into the thoracic cavity and invading the vertebral pedicle (curved arrow). The MR image better depicts the tumor extension in the rib (straight arrow) than does the CT scan. The pleural effusion had increased in size by the time of MR imaging.

Osteosarcoma

Osteosarcomas are malignant mesenchymal neoplasms that rarely occur in the thorax. The rib, scapula, and clavicle are the most frequent sites of origin. Lesions in these osseous sites usually manifest in young adults and may be accompanied by extra pleural masses. Extra osseous osteosarcoma is less common and manifests at a mean age of 50 years (Fig. 10).

Chest wall osteosarcomas typically manifest clinically as painless masses. Local recurrence and metastatic spread to the lungs and lymph nodes are frequent in osteosarcomas in the chest wall, compared with those in the extremities, and contribute to poor survival.

Radiographs typically show calcification or lytic or sclerotic osteoid bone matrix in the mass. An important feature on CT scans is the spatial distribution of areas of mineralization, which is greatest at the center of the lesion and least at the periphery.

MR imaging may depict tumor mineralization, which may have signal intensity higher than that of muscle on T1-weighted images. Mixed but predominantly high signal intensity is observed on T2-weighted images. Large cystic components also may be depicated.[31] The tumor shows heterogeneous enhancement after administration of intravenous contrast material.

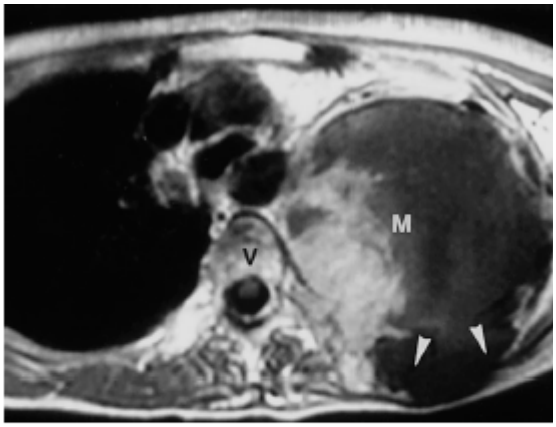

Figure 10. Osteosarcoma in a 25-year-old woman. Axial gadolinium-enhanced T1-weighted (500/15) M image shows a large mass (*M*) with heterogeneous en hancement in the upper left hemithorax. The mass h invaded the posterior chest wall (arrowheads) and fill the thoracic cavity on the left side. *V* = vertebra.

Acknowledgement:
This research was sponsored by the Libyan government.

References:

1. Athanassiadi K, Kalavrouzistis G, Randogianni D, et al. Primary chest wall tumors: early and long-term results of surgical treatment. Eur J Cardiothorac Surg, 2001; 19: 589-593.
2. Jeung M, Gangi A, Gasser B, et al. Imaging of chest wall disorders. Radiographic. 1999; 19: 617-637.
3. Siegel MJ. Magnetic resonance imaging of musculoskeletal soft tissue masses. Radiol Clin North Am, 2001; 39:701-720.
4. McClain K, Leach CT, Jenson HB, et al. Association of Epstein-Barr virus with leiomyosarcomas in children with AIDS. N Engl J, 1995; 332:12-18.
5. Harlman D, Hayes W, Choyke P, et al. Leiomyosarcomas of the retroperitoneum and inferior vena cava: radiographic-pathologic correlation. Radiographics. 1992; 12: 1203-1220.
6. Enzinger F, Weirs S. Leiomyosarcoma. In Enzinger FM, Weiss SW, eds. Soft tissue tumors. 3rd ed. St. Louis, Mo: Mosby, 1995; 491:540.
7. Kransdart MJ. Malignant soft-tissue tumors in a large referral population: distribution of diagnosis by age, sex, and location. AJR AMJ Roentgenol. 1995; 164:129-134.
8. Almberger M, Iannicelli E, Matrunola M, et al. Integrated diagnostic imaging of primary thoracic rhabdomyosaroma. Eur Radio. 2001; 11: 506-508.
9. Meis-Kindblom J, Kindblom L. Angiomyo-sarcoma of soft tissue: a study of 80 cases. Am J Surg Pathol. 1998; 22: 683-697.
10. Coldwell D, Baron R, Charnsangavej C. Angiomyosarcoma: diagnosis and clinical course. Acta Radil. 1989; 30: 627-631.
11. Kazerooni E, Hessler C. CT appearance of angiomyosarcoma associated with chronic lymphedema. AJR Am J Roentgenol. 1991; 156:543-544.
12. Murphey MD, Gross TM, Rosenthal HG. Musculocutaneous malignant fibrous histocytoma: radio-pathologic correlation, Radio Graphics. 1994; 14: 807-828.
13. Fletcher CD, Gustafson P, Rydholm A, et al. Clinicopathologic re-evaluation of 100 malignant fibrous histiocytomas: prognostic relevance of subclassification. J Clin Oncol. 2001; 9:3045-3050.
14. Kabiri EH, A; Aziz S, El Moslout A, et al. Dermoid tumours of the chest wall. Eur J Cardiothorac Surg. 2001; 19: 580-583.
15. Enzinger FM, Weiss SW. Fibromatoses. In Enzinger FM, Weiss SW, eds., Soft-tissue. 3rd ed. St. Louis, Mo: Mosby.1995;201-229.
16. Feld R, Burk DL, McCue P, et al. MRI of aggressive fibromatosis: frequent appearance of high signal intensity on T2-weighted images. Magn Reson Imaging. 1990; 8: 583-588.
17. Ackman JB, Whitman GJ, Chew FS. Aggressive fibromatosis. AJR Am J Roentgenol. 1994; 163: 544.

18. Casillas J, Sais GJ, Greie JL, et al. Imaging of intra and extra-abdomind desmoids tumors. Radio-Graphic. 1991; 11: 959-968.
19. O'Keefe F, Kin E, Wallace S. Magnetic resonance imaging in aggressive fibromatosis. Clin Radiol. 1990; 42: 170-173.
20. Sofka CM, Semelka RC, Kelekis NL, et al. Magnetic resonance imaging of neuroblastoma using current techniques. Magn Reson Imaging. 1999; 17: 193-198.
21. Mainwaring RD, Healy RM, Reilly AF, et al. Shoulder pain in a child, a case presentation of ganglio-neuroblastoma. Del Med J. 2000; 72: 123-125.
22. Longergan GJ, Schwab CM, Suarez ES, et al. Neuroblastoma, ganalio-neuroblastoma, and ganalioneuroma: radio-pathologic correlation. Radiographics. 2002; 22: 911-934.
23. Sordillo PP, Helson L, Hajdu SI, et al. Malignant Schwannomas: clinical characteristic, survival and response to therapy. Cancer. 1981; 47: 2503-2509.
24. Moon WK, Im JG, Han MC. Malignant schwannomas of the thorax: CT findings. J Comput Assist Tomogr. 1993; 17: 274-276.
25. Levine E. Huntrokoon M, Wetzel LH. Malignant nerve-sheath neoplasms in neurofibromatosis: distinction from benign tumors by using imaging techniques. AJR Am J Roentgenol. 1987; 149: 1059-1064.
26. Shapeere LG, Vanel D, Covanet D, et al. Extraskeletal mesenchymal chondrosarcoma. Radiology. 1993; 186: 819-826.
27. Saleh G, Evan H, Ro J, et al. Extraskeletal myxoid chondrosarcoma: a clinicopathologic study of 10 patients with long-term follow-up. Cancer. 1992; 70: 2827-2830.
28. Varma DG, Ayala AG, Carrasco CH, et al. Chondrosarcoma: MR imaging with pathologic correlation. Radio Graphics. 1992; 12: 687-704.
29. Kransdorf MJ, Mess JM. Extraskeletal osseous and cartilagenous tumors of the extremities. Radio-Graphics. 1993; 13: 853-884.
30. De Lang EE, Pope TL, Fechner RE. Dedifferentiated chondrosarcoma: radiographic features. Radiology.1986;161:489-492.
31. Sundaram M, McGuire MH, Herbold DR. Magnetic resonance imaging of osteosarcoma. Skeletal. Radio. 1987; 16: 23-29.